


# Co-existence of Obstructive and Septic Shock in a Patient Identified by Point of Care Ultrasonography: A Case Report

SADANANDA BARIK<sup>1</sup>, NISHIT KUMAR SAHOO<sup>2</sup>, SATYABRATA GURU<sup>3</sup>, AJITESH SAHU<sup>4</sup>, UPENDRA HANSDA<sup>5</sup>



## ABSTRACT

Shock is a state of acute circulatory failure leading to decreased organ perfusion, inadequate delivery of oxygenated blood to tissues, and resultant end-organ dysfunction. A 45-year-old male patient a known case of Diabetes Mellitus (DM) presented to the Emergency Room (ER) with a complaint of fever for four days and shortness of breath for one day. The patient had a wound discharging pus over the dorsum of the right foot for two weeks following trauma. On examination, the patient's vitals were: pulse rate-88 Beats Per Minute (bpm), respiratory rate-26 breaths per minute, Oxygen Saturation (SpO<sub>2</sub>)-78% room air, Blood Pressure (BP)-82/40 mmHg mean arterial pressure- 54 mmHg. As a protocol of shock evaluation, Point of Care Ultrasonography (POCUS) showed a distended Inferior Vena Cava (IVC), dilated right atrium and ventricle, and good left ventricular systolic function. Given the presence of right leg swelling, ultrasound was done, which showed a thrombus in the popliteal vein. Noradrenaline infusion was started to maintain a mean arterial blood pressure of 70 mmHg. A diagnosis of obstructive shock due to pulmonary embolism was strongly suspected, and thrombolysis with injection streptokinase was done. After two hours of thrombolysis, Two-Dimensional (2D) Echocardiography (ECHO) revealed normal right atrium and ventricle size and IVC collapsibility index of 70%, but the patient's blood pressure didn't improve significantly. So, adequate intravenous fluid was given as per the septic shock protocol. But, the noradrenalin requirement didn't improve. The patient was put on broad-spectrum antibiotics. Blood culture showed growth of *Pseudomonas aeruginosa*. So, a diagnosis of co-existing septic shock with obstructive shock was made. The patient improved and discharged in stable condition. The present case report highlights the co-existence of septic shock and obstructive shock and the usefulness of POCUS in differentiating and managing various shocks.

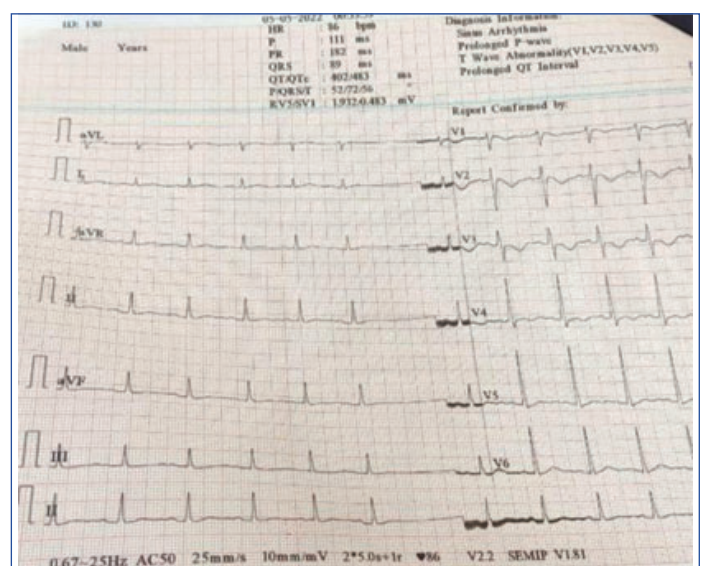
**Keywords:** Deep vein thrombosis, Pulmonary embolism, Sepsis, Streptokinase, Thrombolysis

## CASE REPORT

A 45-year-old male was presented to the ER of All India Institute of Medical Sciences (AIIMS), Bhubaneswar, Odisha, India, with the complaint of high grade fever for four days, shortness of breath and altered sensorium, and generalised weakness for two days. The patient had a wound discharging pus over the dorsum of the right foot for two weeks following trauma. Following this, the patient was bed bound with limited movement. The patient has been a known diabetic for the past ten years, taking oral antidiabetic drugs irregularly. The patient has been a smoker for 20 years and is not an alcoholic and was not a known case of chronic respiratory illness, cardiac illness, or hypertension. No history of any surgery in the past. There was no history of bleeding or coagulation disorder in any family members. On examination patient was conscious and oriented (Glasgow coma scale E3 M5 V4). The vitals were pulse rate-88 bpm, respiratory rate-26 breaths/minute, SpO<sub>2</sub>-78% room air, BP-82/40 mmHg {(mean arterial pressure-54 mmHg)}, temperature-101°F. Random blood sugar was 178 mg/dL. Extremities were cold and neck veins were distended. Chest auscultation revealed normal vesicular breath sounds with no added sound. The right lower limb was swollen with an ulcer over the dorsum of the right foot. The ulcer was 5x5 cm, had a red margin and necrotic base, and was discharging foul smelling pus. It was an infected diabetic ulcer.

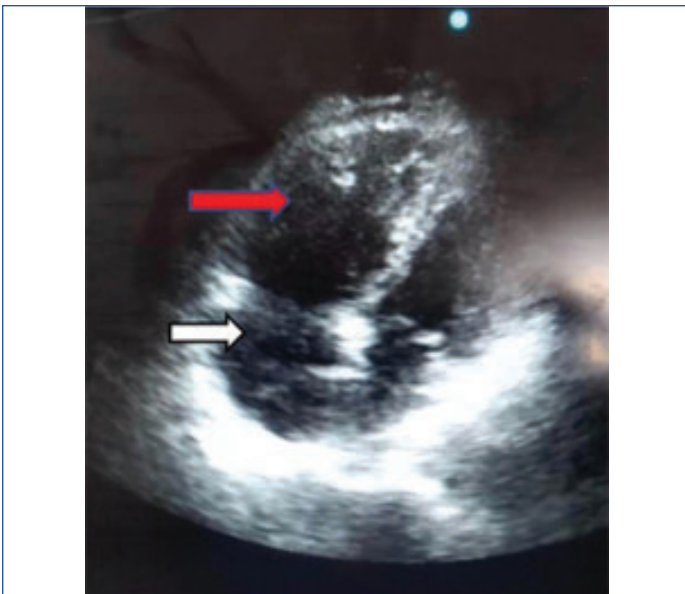The Electrocardiogram (ECG) showed sinus rhythm with t-wave inversion in lead V1, V2, V3, and V4 and QT interval prolongation (QTc-483ms) [Table/Fig-1]. Arterial blood gas analysis showed pH 7.398, partial pressure of Carbon Dioxide (pCO<sub>2</sub>)-28.6 mmHg, partial pressure of Oxygen (pO<sub>2</sub>)-56 mmHg, Bicarbonate (HCO<sub>3</sub><sup>-</sup>)-27 mmol/L, lactate 2.1 mmol/L, sodium 132 mmol/L, potassium-3.67 mmol/L and Ca<sup>++</sup>1.05 mmol/L. POCUS showed distended IVC collapsibility index 9%, dilated right atrium and ventricle, and

normal left ventricular systolic function with no regional wall motion abnormality [Table/Fig-2]. Compression sonography of the bilateral lower limb revealed an echogenic thrombus in the right popliteal vein [Table/Fig-3]. Ultrasound of both lung fields was normal. The D-dimer value was 1.34 mg/L Fibrinogen Equivalent Units (FEU) (normal reference value is <0.5 mg/L FEU).

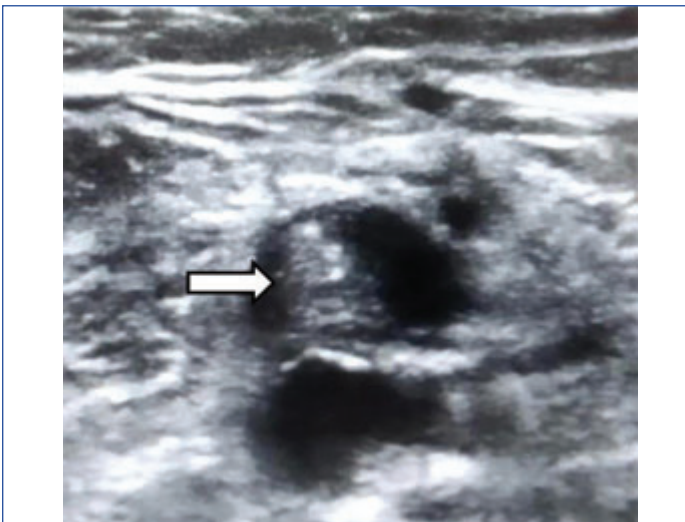


**[Table/Fig-1]:** Lead electrocardiogram showing sinus rhythm, the normal axis with t-wave inversion in lead V1, V2, V3, V4 and QT prolongation.

Because of the above clinical and ultrasound picture, a diagnosis of obstructive shock due to pulmonary embolism was strongly suspected. Oxygen inhalation was started through a high flow nasal cannula at the rate of 10/minute, with which SpO<sub>2</sub> improved



**[Table/Fig-2]:** A 2D ECHO apical four-chamber view showing dilated right atrium (white arrow).



**[Table/Fig-3]:** Ultrasound showing non compressible echogenic shadow in right popliteal vein suggestive of thrombus (white arrow).

to 98%. With a noradrenalin infusion rate of 18 mcg/minute, BP improved to 90/65 mmHg (mean arterial pressure 73 mmHg). To relieve obstruction, an accelerated regimen of streptokinase (1.5 million IU over two hours) was given for thrombolysis. After thrombolysis, patient improved significantly, respiratory rate decreased to 16 breaths/minute, oxygen requirement decreased to 4 L/minute through a face mask, noradrenalin infusion dose was reduced from 18 mcg/minute to 6 mcg/minute, peripheries became warm, and neck vein distention disappeared. 2D ECHO revealed a return of dilated right atrium and ventricle to normal size and collapsed IVC collapsing index 70%. Given the above parameters, a successful thrombolysis was confirmed. But, the patient continued to remain in a shock state requiring noradrenalin support. Intravenous fluid bolus was administered as per septic shock protocol, but the noradrenalin requirement didn't improve. So, a provisional diagnosis of co-existing septic shock was made.

Intravenous Piperacillin-Tazobactam and injection Linezolid was administered after sending the necessary specimens for cultures. After six hours of ER stay patient was shifted to ICU for further treatment. Local wound debridement was done. Blood culture reports revealed *Pseudomonas aeruginosa* was sensitive to Piperacillin and Tazobactam. The patient slowly improved, and the noradrenalin infusion was tapered off after five days and shifted to the ward. The patient was discharged in stable condition after 10 days.

## DISCUSSION

Shock is a state of acute circulatory failure leading to decreased organ perfusion, inadequate delivery of oxygenated blood to tissues, and resultant end-organ dysfunction. Early identification and the start of treatment play a crucial role in its outcome [1]. It is broadly classified into hypovolemic, distributive, cardiogenic, and obstructive shock. The common cause of shock in the ER is hypovolemic (30.8%) and septic shock (27.2%), followed by cardiogenic shock (14%) [2]. Obstructive shock is rare, seen only in 0.9%. POCUS is now widely available in the Emergency Department (ED) and Intensive Care Unit (ICU) and rapid evaluations of fluid status and cardiac and pulmonary function. POCUS helps in the early diagnosis of a hypotensive patient in ER, so that, appropriate treatment can be immediately started [3].

A systematic review found POCUS helpful in diagnosing undifferentiated shock in the ER [4]. In a patient with acute pulmonary embolism with hemodynamic instability, thrombolysis reduces the death rate and pulmonary embolism recurrence [5]. Haemodynamic instability is characterised by cardiac arrest, obstructive shock and persistent hypotension. Obstructive shock is defined as systolic BP < 90 mmHg or vasopressors required to achieve a BP > 90 mmHg despite adequate filling status and end-organ dysfunction [6]. Thrombolytic therapy leads to rapid improvements in pulmonary pressure, accompanied by RV dilation on echocardiography [7]. Surviving sepsis campaign International guidelines for managing sepsis and septic shock, 2021 suggest infusing 30 mL/kg of intravenous crystalloid for septic shock patients for initial resuscitation. The noradrenalin infusion is strongly recommended if mean arterial pressure doesn't improve with fluid therapy [8].

Two or more types of shock can co-exist in a patient, posing diagnostic and management challenges to the emergency physician. There was one reported case of combined septic and obstructive shock. Zanobetti M et al., reported a case of combined septic and obstructive shock, and they demonstrated the utility of bedside POCUS and 2D echocardiography [9]. In the present case, the cause of obstructive shock was an extension of the right lung mass into the right ventricle, causing occlusion of the tricuspid valve. In index patient, obstructive shock due to acute pulmonary embolism and septic shock co-existed with immediate thrombolysis for acute obstructive shock due to pulmonary embolism and subsequent treatment of septic shock helped the patient's complete recovery.

## CONCLUSION(S)

The present case shows the importance of bedside POCUS in identifying the co-existence of more than one kind of shock in a patient in the ER in a very short time. This helps in the early start of appropriate therapy, which will change the outcome of the patients.

## REFERENCES

- [1] Vincent JL, De Backer D. Circulatory shock. *N Engl J Med*. 2014;370(6):583.
- [2] Holler JG, Jensen HK, Henriksen DP, Rasmussen LM, Mikkelsen S, Pedersen C, et al. Etiology of shock in the emergency department: A 12-year population-based cohort study. *Shock*. 2019;51(1):60-67.
- [3] Sasmaz MI, Gungor F, Guven R, Akyol KC, Kozaci N, Kesapli MI. Effect of focused bedside ultrasonography in hypotensive patients on the clinical decision of emergency physicians. *Emerg Med Int*. 2017;2017:6248687.
- [4] Berg I, Walpot K, Lamprecht H, Valois M, Lanctot JF, Srour N, et al. A systemic review on the diagnostic accuracy of point of care ultrasound in patients with undifferentiated shock in the emergency department. *Cureus*. 2022;14(3):e23188.
- [5] Marti C, John G, Konstantinides S, Combes C, Sanchez O, Lankeit M, et al. Systemic thrombolytic therapy for acute pulmonary embolism: A systematic review and meta-analysis. *Eur Heart J*. 2015;36(10):605-14.
- [6] Konstantinides SV, Meyer G, Becattini C, Bueno H, Geersing GJ, Harjola VP, et al. 2019 ESC Guidelines for the diagnosis and management of acute pulmonary embolism developed in collaboration with the European Respiratory Society (ERS). *Eur Heart J*. 2020;41(4):543-603.
- [7] Goldhaber SZ, Haire WD, Feldstein ML, Miller M, Toltzis R, Smith JL, et al. Alteplase versus heparin in acute pulmonary embolism: Randomized trial. Assessing right-ventricular function and pulmonary perfusion. *Lancet*. 1993;341(8844):507-11.

- [8] Evans L, Rhodes A, Alhazzani W, Antonelli M, Coopersmith CM, French C, et al. Surviving sepsis campaign: International guidelines for management of sepsis and septic shock 2021. *Intensive Care Med.* 2021;47(11):1181-247.
- [9] Zanobetti M, De Villa E, Lazzeretti D, Conti A, Pinni R. A case of combined septic and obstructive shock: Usefulness of bedside integrated cardiothoracic emergency ultrasonography. *Case Rep Emerg Med.* 2013;2013:154861.

**PARTICULARS OF CONTRIBUTORS:**

1. Assistant Professor, Department of Trauma and Emergency Medicine, All India Institute of Medical Sciences, Bhubaneswar, Odisha, India.
2. Junior Resident, Department of Trauma and Emergency Medicine, All India Institute of Medical Sciences, Bhubaneswar, Odisha, India.
3. Assistant Professor, Department of Trauma and Emergency Medicine, All India Institute of Medical Sciences, Bhubaneswar, Odisha, India.
4. Assistant Professor, Department of Trauma and Emergency Medicine, All India Institute of Medical Sciences, Bhubaneswar, Odisha, India.
5. Associate Professor, Department of Trauma and Emergency Medicine, All India Institute of Medical Sciences, Bhubaneswar, Odisha, India.

**NAME, ADDRESS, E-MAIL ID OF THE CORRESPONDING AUTHOR:**

Sadananda Barik,  
I-O51, Cosmopolis Apartment, Khandagiri, Bhubaneswar-751019, Odisha, India.  
E-mail: kdsada@gmail.com

**PLAGIARISM CHECKING METHODS:** [\[Jain H et al.\]](#)

- Plagiarism X-checker: Feb 28, 2023
- Manual Googling: Apr 17, 2023
- iThenticate Software: Apr 21, 2023 (4%)

**ETYMOLOGY:** Author Origin**EMENDATIONS:** 5**AUTHOR DECLARATION:**

- Financial or Other Competing Interests: None
- Was informed consent obtained from the subjects involved in the study? Yes
- For any images presented appropriate consent has been obtained from the subjects. Yes

Date of Submission: **Feb 18, 2023**Date of Peer Review: **Mar 20, 2023**Date of Acceptance: **Apr 22, 2023**Date of Publishing: **Jul 01, 2023**